

# In Vivo Kinematics for Subjects Implanted With Either a Traditional or a Customized, Individually Made TKA

Kurtz, WB; Zeller, IM; Hamel, WH; Young, MA; Anderle MR; Komistek, RD

Presented at the proceedings of ICJR Pan-Pacific 2014, Abstract #O21A2

## INTRODUCTION

Until recently, knee implants were designed using average patient measurements. More recently, using imaging techniques, patient specific posterior cruciate retaining (PCR) total knee arthroplasty (TKA) implants have been individually made based on each patient's anatomy using a pre-operative CT scan. The objective of this study was to use a state-of-the-art mobile fluoroscopy unit to determine the in vivo kinematics for subjects having either a traditional, off-the-shelf (OTS) knee implant or a customized, individually made (CIM) knee implant that replicates each patient's femoral and tibial geometries.

## METHODS

In vivo kinematics for 20 subjects, 11 having a CIM TKA (iTotal, ConforMIS, Inc., Bedford, MA) and 9 having an OTS TKA (NexGen, Zimmer USA, Warsaw, IN), were assessed. A mobile fluoroscopic system was used and each patient was asked to perform a weight-bearing deep knee bend and a chair rise under fluoroscopic observation. Those fluoroscopic 2D images were then converted into a 3D representation of actual kinematics. All the subjects were implanted by a single surgeon and each patient was deemed clinically successful (KSS Score >90) without any laxity or pain. Comparison of kinematics between the two designs focused on range of motion, posterior femoral rollback and axial rotation.

## RESULTS

Differences in overall motion and pattern were evident between the two groups. During a deep knee bend, subjects with a CIM TKA experienced  $112^\circ$  of weight-bearing flexion, compared to only  $102^\circ$  for subjects with an OTS TKA. Subjects having a CIM knee implant experienced more posterior femoral rollback of their lateral condyle (2.1 vs. 0.1 mm) and greater axial rotation (4.2 vs.  $2.9^\circ$ ) than subjects with OTS TKA type. Also, 44.4% of the subjects with an OTS TKA experienced an anterior slide of their lateral condyle and a reverse axial rotation pattern, compared to only 9.0% of the subjects with a CIM TKA. Additionally, 56% of patients in the OTS TKA group experienced condylar lift-off >1.0mm compared to 0% of patients in the CIM TKA group (Figure 1). During the chair-rise activity, subjects with an OTS TKA experienced a posterior slide of their lateral condyle opposite the normal knee, while subjects with a CIM TKA experienced a roll forward motion (Figure 2) typical in pattern for a normal knee. The OTS TKA experienced  $0.9^\circ$  of axial rotation, while subjects with a CIM TKA experienced  $5.3^\circ$ . Interestingly, subjects with an OTS TKA experienced high magnitudes of femoral external rotation (opposite the normal knee), whereas the CIM TKA subjects experienced a change from external to internal rotation of the femur (similar to the pattern of a normal knee).

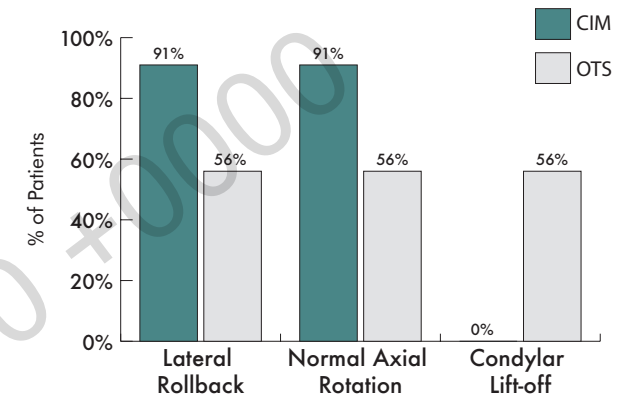


Figure 1: Comparison of Deep Knee Bend kinematics between the CIM and OTS TKA arms.

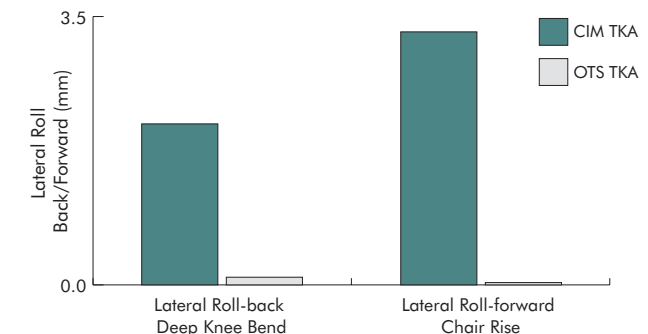


Figure 2: Comparison of average anterior/posterior translation for the CIM and OTS TKAs during Deep Knee Bend and Chair Rise.

## DISCUSSION

Subjects with a CIM TKA experienced a kinematic pattern similar to a normal knee. Subjects with an OTS TKA experienced greater variability in their kinematic patterns, differing from the normal knee. This is the first study to utilize mobile fluoroscopy to assess deep knee bend, chair-rise and gait for subjects having two distinctly different TKA types.